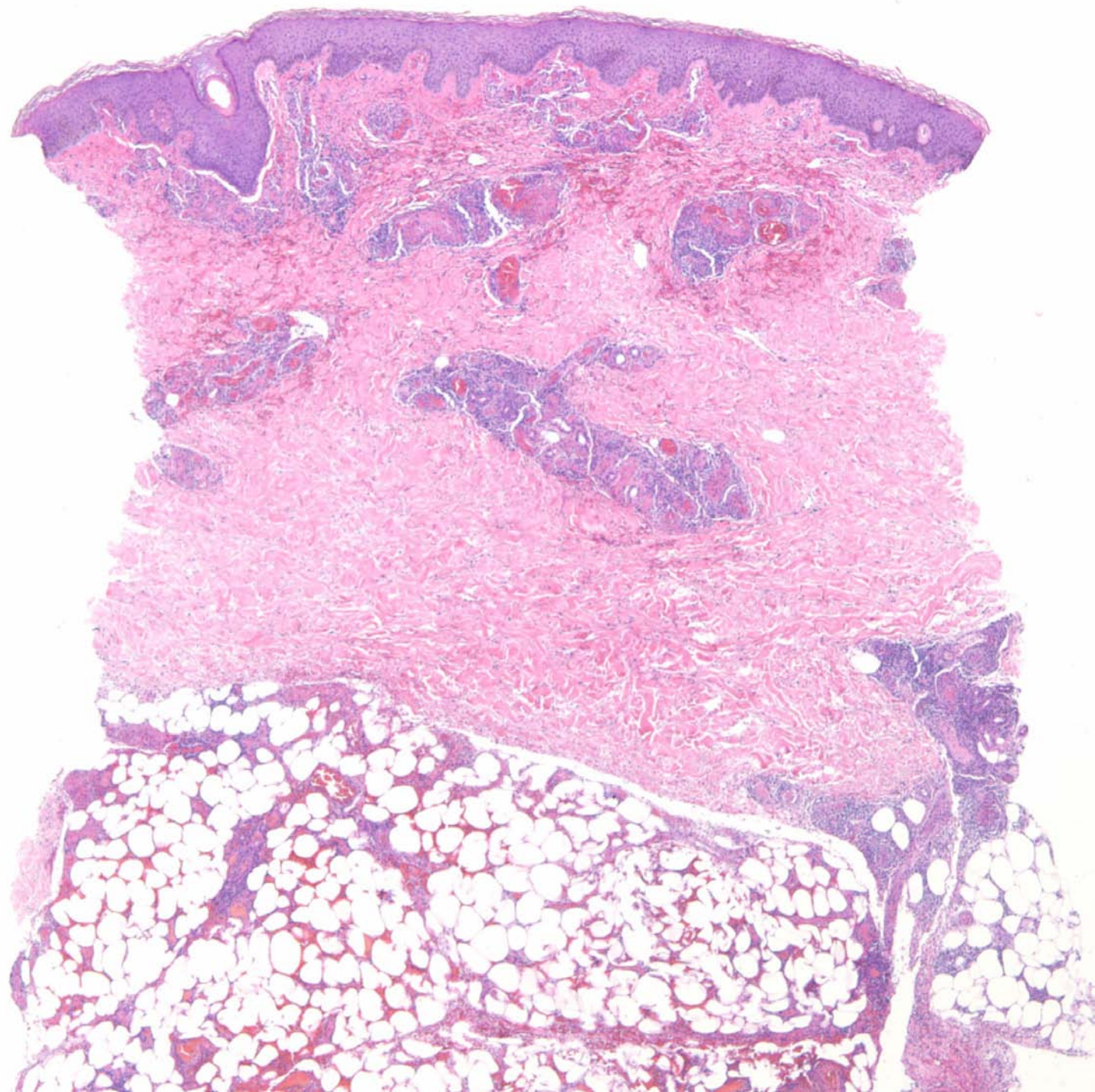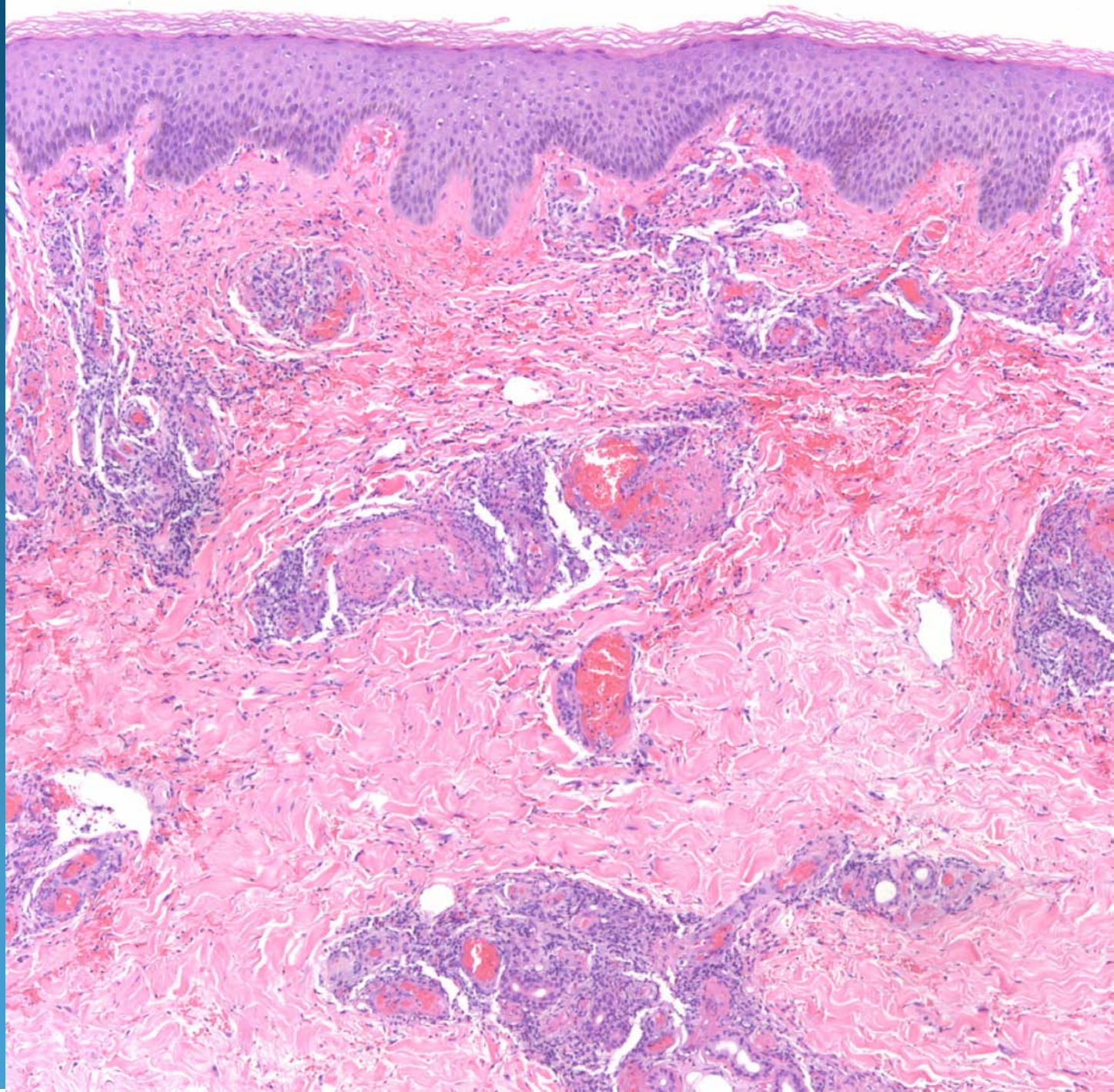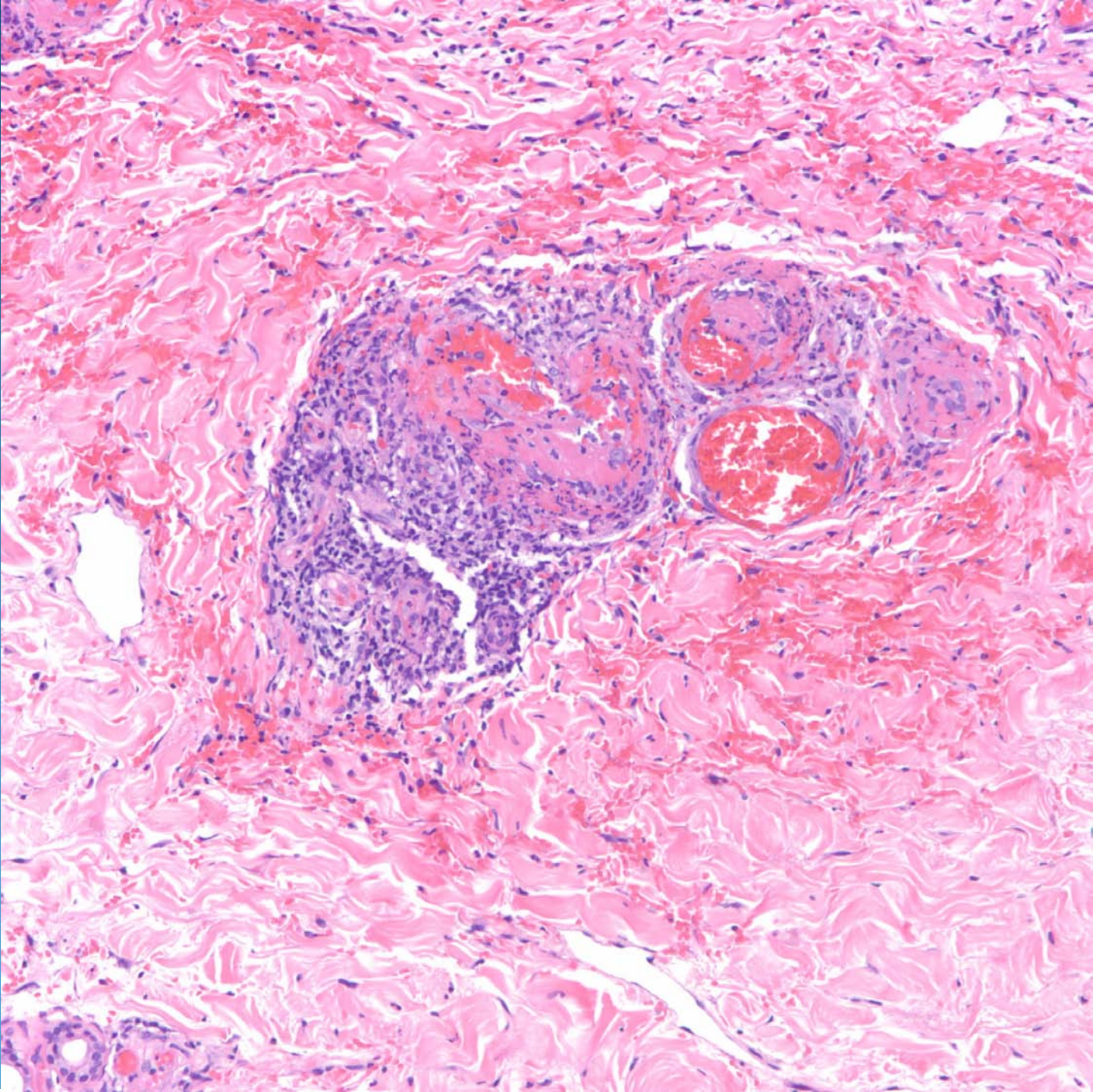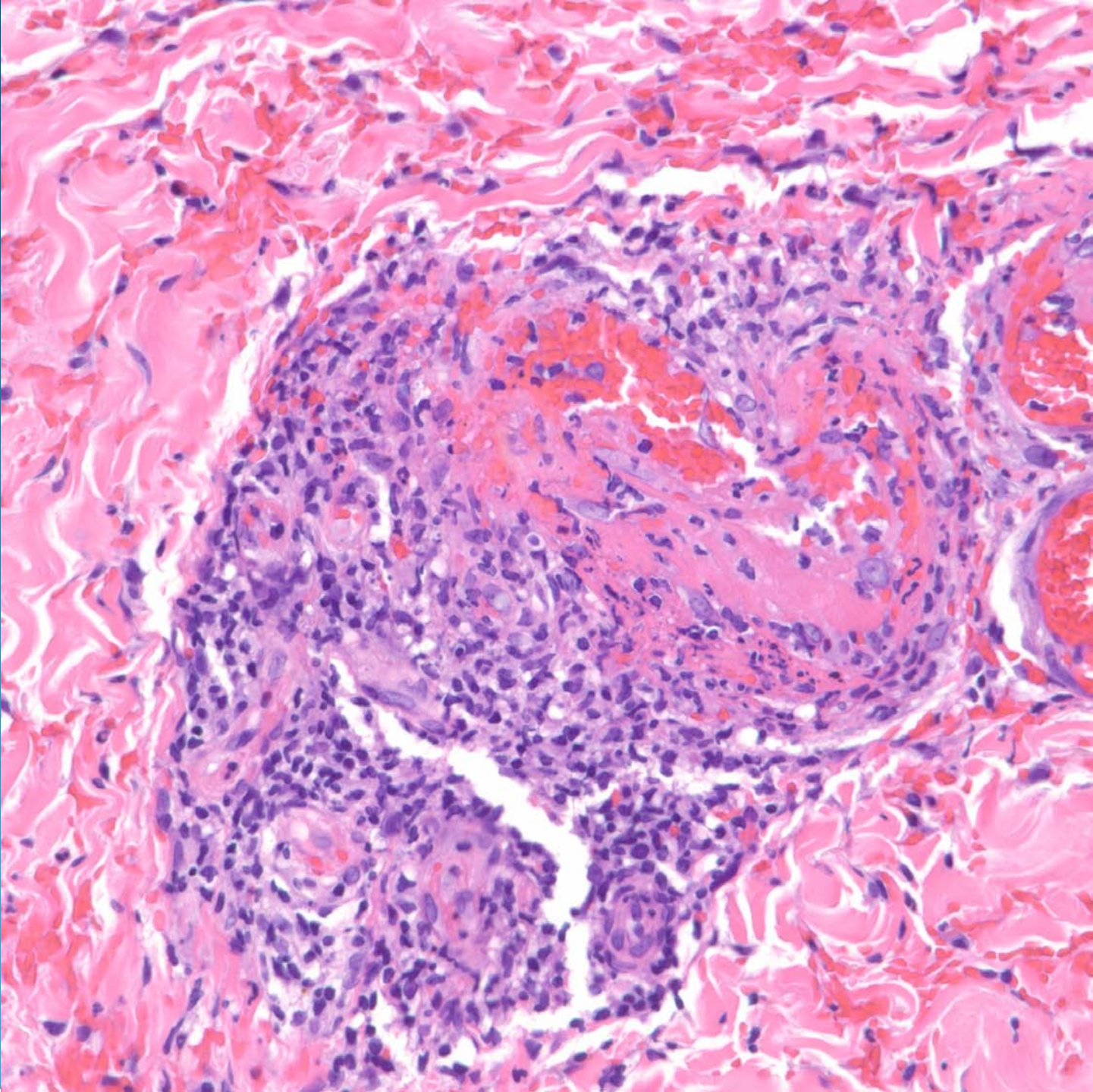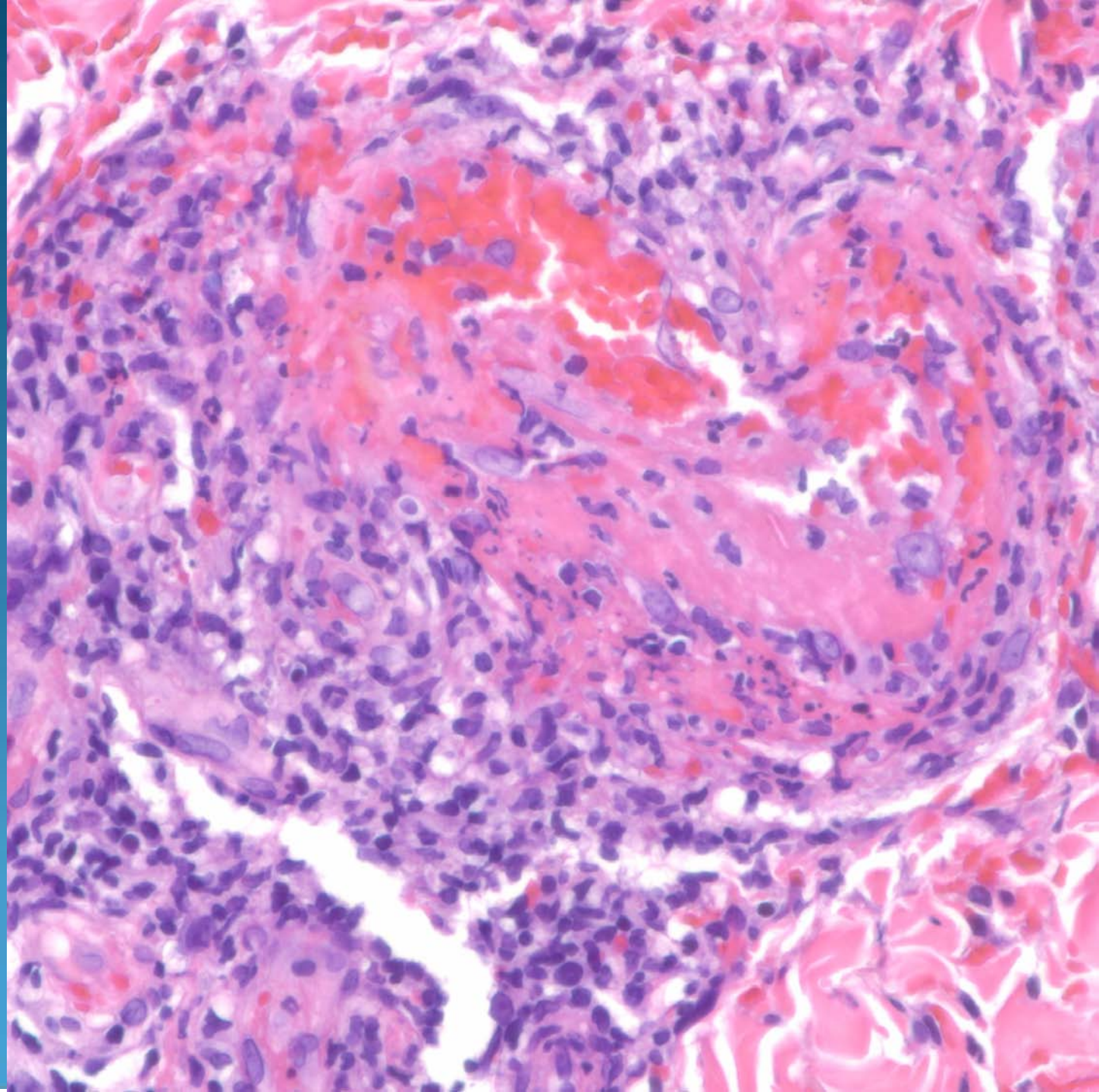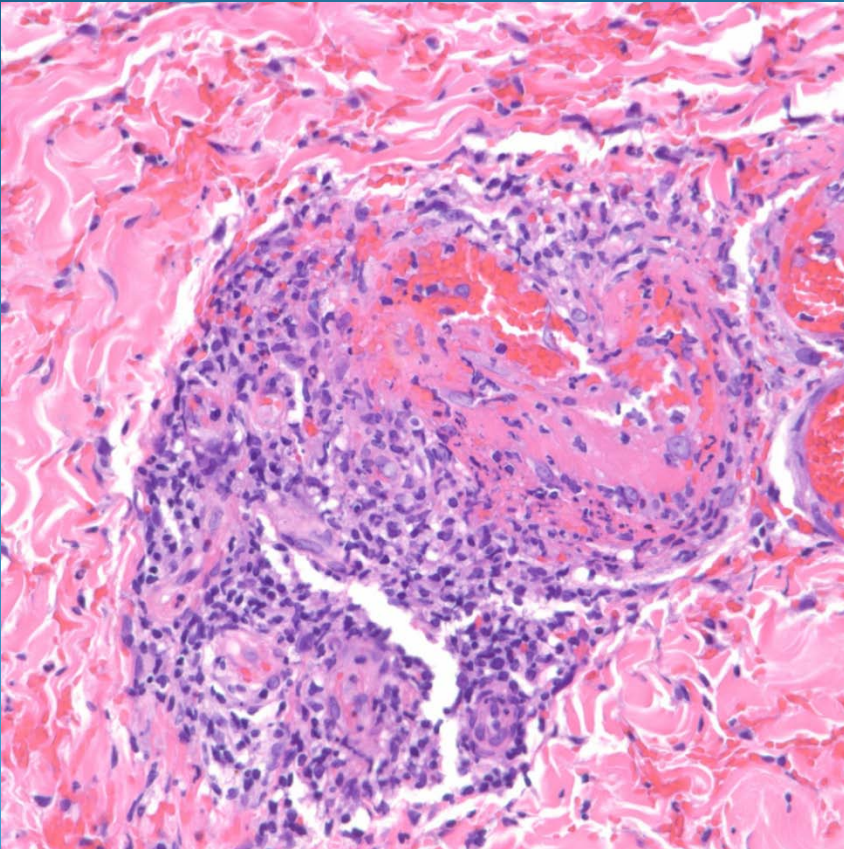


Thrombotic Vasculopathy

Pearls



- Look for eosinophilic material occluding vessels, distinguish from red blood cells
- Vessels may show hyalinization and fibrin with scattered neutrophils
- Investigate coagulation deficiencies (Anti-thrombin III, Factor V Leiden, Protein C&S, etc)